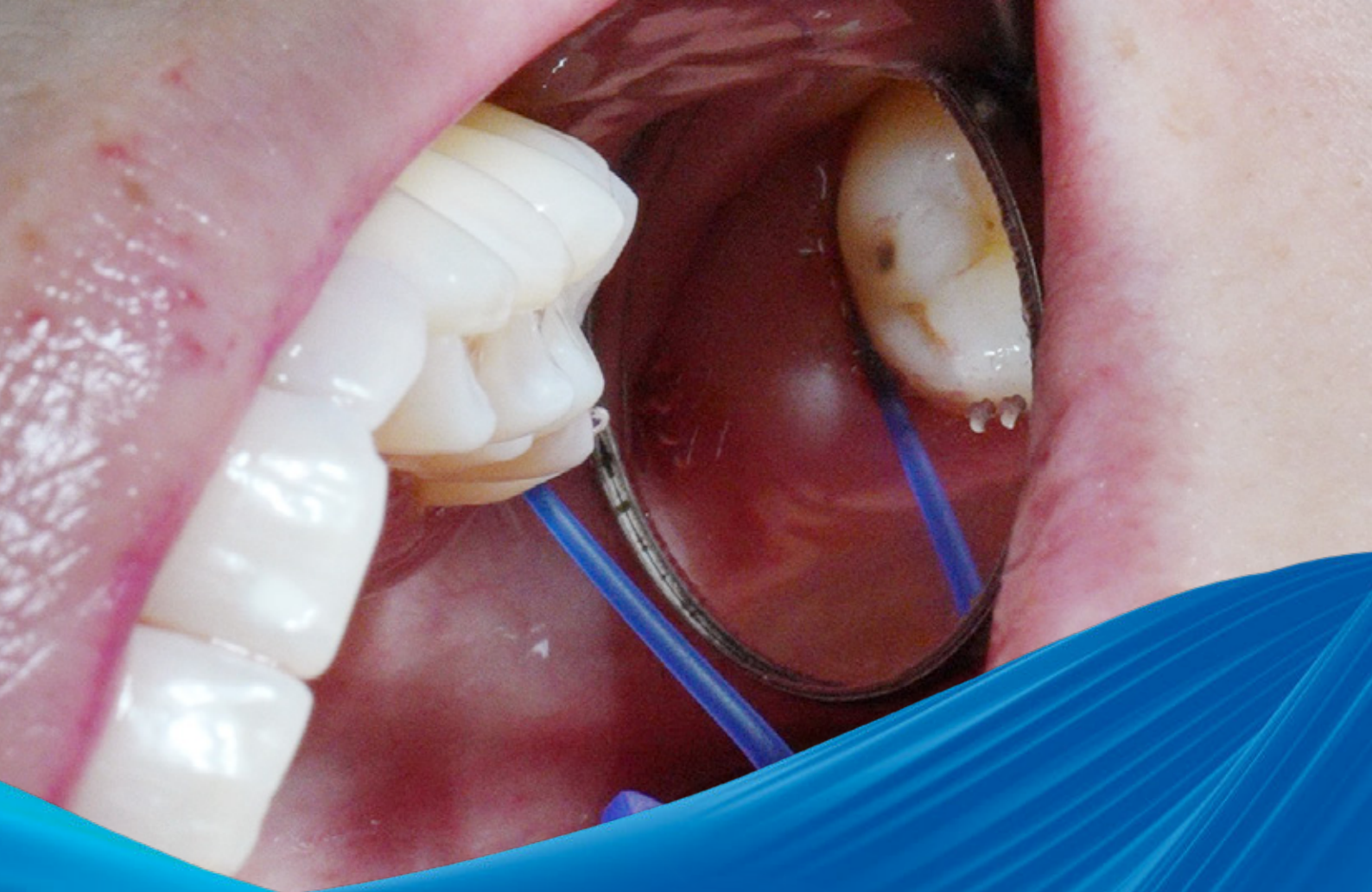



BioBrief

NON-SURGICAL PERIODONTAL TREATMENT

Curious
about other
BioBriefs?

bio-brief.com



Prof. Dr. Peter Hahner

Pocket-X® Gel in non-surgical
periodontal treatment

leading regeneration

Geistlich

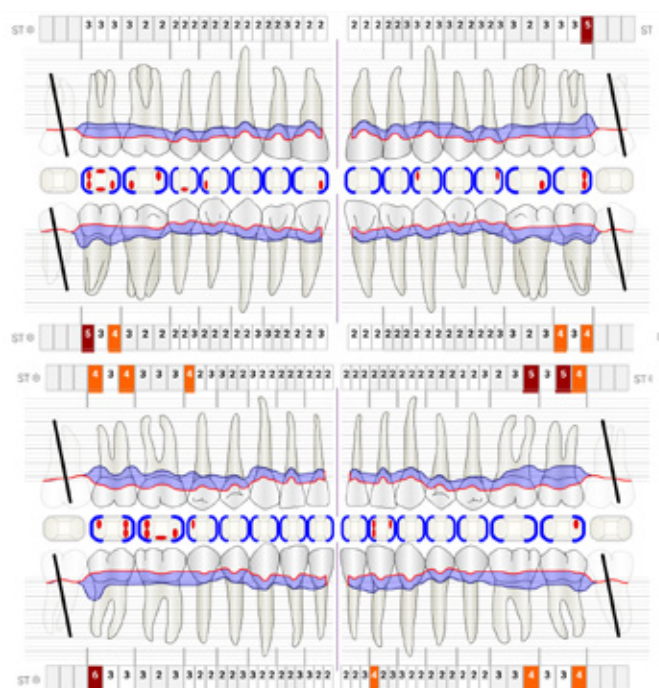
The Situation

An adult female patient (age 37 years, systemically healthy, non-smoker) in supportive periodontal therapy (Step 4 according to EFP guideline, first re-evaluation after active periodontal treatment 4 months before) presented with persistent periodontal pockets 4-6 mm with recurring bleeding on probing in posterior regions. The primary goal was to establish clinical periodontal health and periodontal stability, at the patient's request preferably without means of surgical interventions.

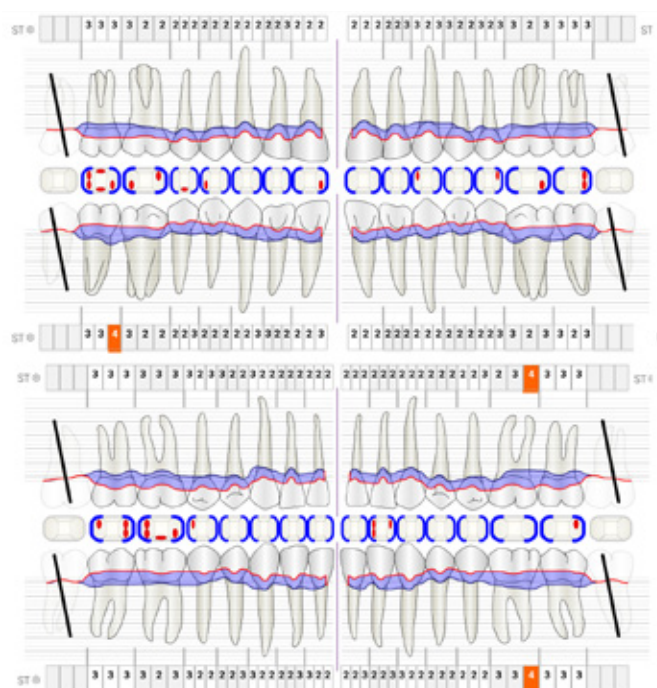
The Approach

As part of regular supportive periodontal therapy, subgingival re-instrumentation of the still inflamed sites was planned. After recording of periodontal parameters, supra- and subgingival biofilm removal was performed using Airflow®/Perioflow® with Erythritol powder, followed by removal of the mineralised deposits using ultrasonic instruments. Pocket-X® Gel was then instilled in all periodontal pockets with probing depths ≥ 4 mm and bleeding on probing, or probing depths ≥ 5 mm.

The Periodontal Status



Before: Initial situation. Diagnosis: Periodontitis Stage 3 Grade B. ST = probing depth in mm.



After: Results 3 months after treatment with Pocket-X® Gel: Reduction of probing depth at teeth 17, 27, 37, 36, 32, 45, 47; Reduction of bleeding on probing; Additional diagnosis of clinical periodontal health (closed pockets) at teeth 27, 37, 36, 32, 45, 47.

Prof. Dr. Peter Hahner

- Cologne
- DMD University Düsseldorf, M.Sc. Periodontics

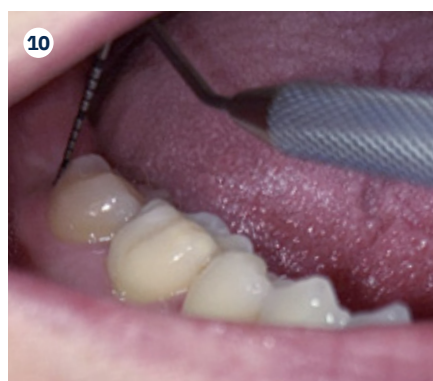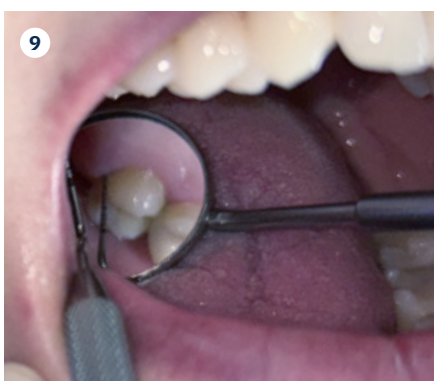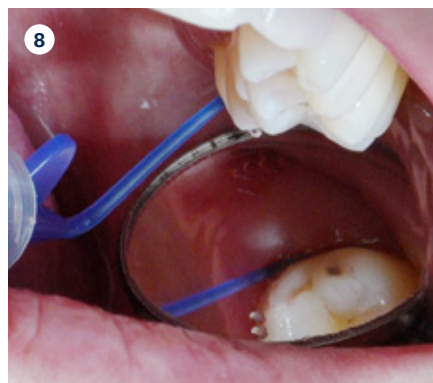
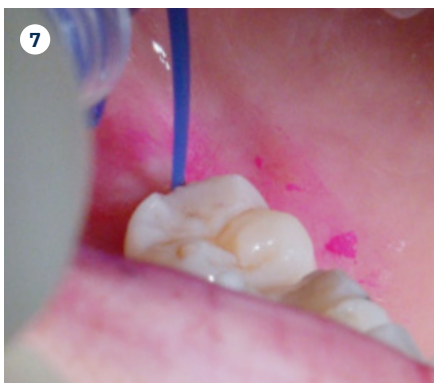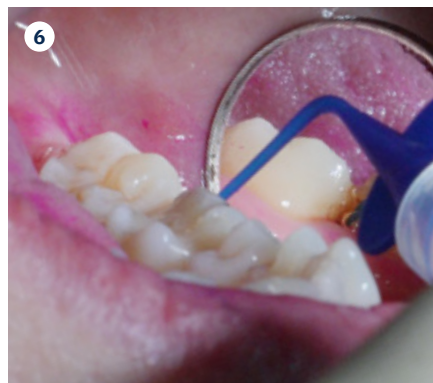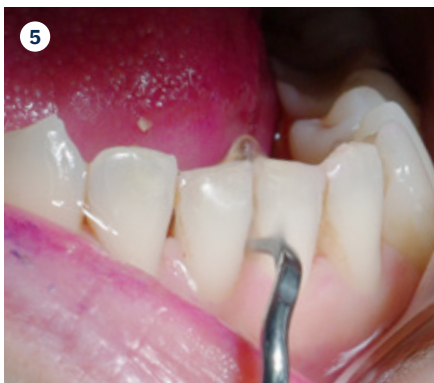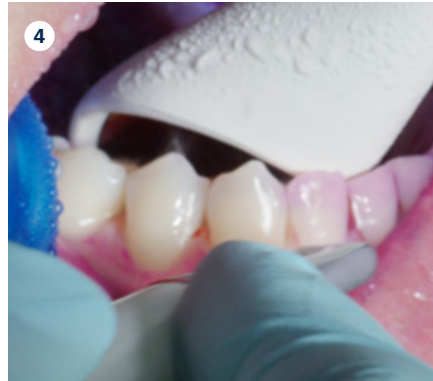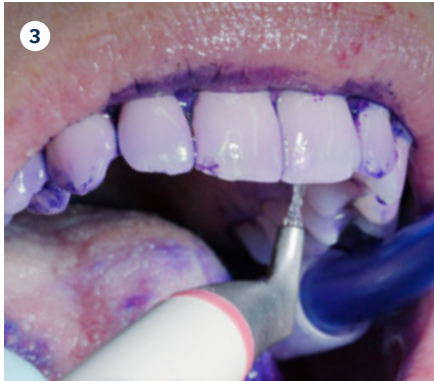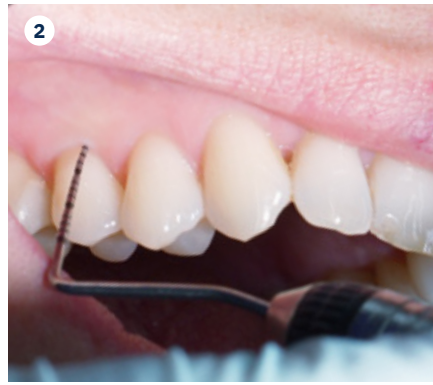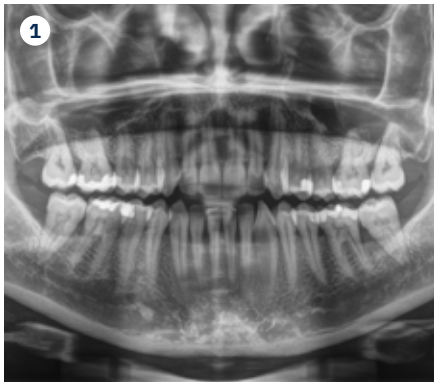1989/1992 State examination/Doctorate (Dr. med. dent.), Düsseldorf University
 1990 Military service: Captain in the medical corps
 Since 1991 Dentist in private practice, Cologne, specialized on periodontology
 2005 M.Sc. (Periodontology), Krems University
 2014/2019 Professor of clinical periodontology at praxisHochschule/EU|FH, Cologne



“The use of a thermo-sensitive gel containing hyaluronic acid in the composition of Pocket-X® Gel is an enrichment of the therapeutic spectrum in non-surgical periodontal therapy. It is quite conceivable that this will further extend the indication limits for minimally invasive non-surgical therapy.”

The Outcome

In the present case study, it was shown that the adjunctive use of a thermo-sensitive gel containing hyaluronic acid in the form of Pocket-X® Gel improved the healing result after subgingival debridement during non-surgical periodontal treatment. Pocket-X® Gel has shown to exceed the commonly reported results on the reduction of probing depths and attachment level gain known from classical studies (e.g. Cobb, 1996).¹



1 X-ray before treatment

Moderate horizontal bone loss, particularly in the molar regions and at the mandibular anterior teeth. Two-wall interdental bone pockets are suspected on teeth 36-37 and 46-47.

2 Diagnosis

Probing pocket depth: Appointment started with re-evaluation of periodontal parameters (probing depths, clinical attachment level, bleeding on probing, plaque index).

3 Supragingival biofilm control

Colouring with biofilm disclosure.

4 Supragingival biofilm control

Biofilm removal with erythritol powder.

5 Supra- and subgingival instrumentation

Removal of mineralized deposits: minimal invasive approach with slim right/left curved ultrasonic tips and minimal power setting to conserve cementum root dentin. No intentional root planing!

6 Results after subgingival instrumentation

The gingiva is not damaged thanks to the minimally invasive instrumentation. Starting the application of Pocket-X® Gel.

7 Adjunctive treatment

Application of Pocket-X® Gel: Inserting the blue syringe tip completely into the periodontal pocket.

8 Adjunctive treatment

Filling the pocket completely with the thermogelling Pocket-X® Gel to protect against bacterial recolonization.

9 Follow-up

Probing pocket depth: Re-evaluation 3 months after intervention.

10 Follow-up

Re-evaluation 3 months after intervention.



Click or scan
to access
the webinar



More details about our distribution partners:
www.geistlich-dental.com

Manufactured exclusively for Prudentix Ltd.

POB 799
Lod 7110604, Israel
www.prudentix.com

Manufacturer

Tree of Life Pharma Ltd.
POB 799
Lod 7110604, Israel

Distribution partner

Geistlich Pharma AG
Business Unit Dental
Bahnhofstrasse 40
6110 Wolhusen, Switzerland
www.geistlich-dental.com

Affiliate Germany

Geistlich Biomaterials
Vertriebsgesellschaft mbH
Schöckstrasse 4
76534 Baden-Baden
www.geistlich.de

Affiliate United Kingdom, Ireland

Geistlich Sons Limited
Thorley House
Bailey Lane
Manchester Airport
Manchester M90 4AB
www.geistlich.co.uk

Affiliate Italy

Geistlich Biomaterials Italia S.r.l.
Via Castelletto, 28
36016 Thiene VI
www.geistlich.it

Affiliate France

Geistlich Pharma France SA
Parc des Reflets
165 avenue du Bois de la Pie
CS 43073
95913 ROISSY CDG Cedex
www.geistlich.fr



Keys to success

- Minimally invasive, atraumatic subgingival instrumentation
- Thorough biofilm removal
- Minimal tissue trauma
- Filling pockets completely with Pocket-X® Gel
- Instructing the patient on aftercare and compliance



Instruments and materials used

Instruments for biofilm control:

- Airflow®/Perioflow® with Erythritol powder (Airflow® plus)

Instruments for calculus removal (supra- and subgingival):

- Piezon® Handpiece with PSL/PSR instruments
- Optional supplementary at selected sites: Mini-five curettes

Rinsing/Irrigation:

- No additional irrigation was used

Adjunctive Treatment:

- Pocket-X® Gel

Learn more about Pocket-X® Gel



VISIT OUR WEBSITE!



Product availability may vary from country to country.

Reference

- 1 Cobb CM: Annals of Periodontology 1996; 1(1): 443–90.